

**Outcome of permanent anterior teeth with a longitudinal study**

<sup>1</sup>Roger Kelio Castro, School of Dental Sciences, Pontifical Catholic University of Rio Grande do Sul, Porto Alegre, Brazil.

<sup>2</sup>Giovana Dereira Pcalco, School of Dental Sciences, Pontifical Catholic University of Rio Grande do Sul, Porto Alegre, Brazil.

**Corresponding Author:** Roger Kelio Castro, School of Dental Sciences, Pontifical Catholic University of Rio Grande do Sul, Porto Alegre, Brazil.

**Citation This Article:** Roger Kelio Castro, Giovana Dereira Pcalco, “Outcome of permanent anterior teeth with a longitudinal study”, IJHDC – September – October - 2022, Vol. – 1, Issue - 1, P. No. 09 – 15.

**Open Access Article:** This is an Open Access article that uses a funding model which does not charge readers or their institutions for access and distributed under the terms of the Creative Commons Attribution License (<http://creativecommons.org/licenses/by/4.0>) and the Budapest Open Access Initiative (<http://www.budapestopenaccessinitiative.org/read>), which permit unrestricted use, distribution, and reproduction in any medium, provided original work is properly credited.

**Type of Publication:** Original Research Article

**Conflicts of Interest:** Nil

**Abstract**

**Aim:** To assess the outcome of pulpotomy using bioceramic material in permanent anterior teeth with traumatic pulp exposure based on clinical and radiographically evaluation.

**Rationale:** To preserve the vitality of the tooth

**Background and objectives:** Traumatic injuries to anterior permanent teeth are more common in which complicated crown fracture needs special attention. Preservation of pulp vitality is important rather than replace it with a root filling material following pulp exposure. This study evaluates the treatment outcome following pulpotomy using bioceramic materials in traumatized mature permanent anterior teeth based on clinical evaluation at 3,6,12 months follow-up and radiographic evaluation at 12 months or any time during the follow-up period if symptomatic. Clinically visible

coronal discoloration and diffuse calcification were also assessed.

**Clinical Description**

In this, study 60 patients of the age group 12-50 years satisfying the inclusion criteria were enrolled. Pulpotomy was performed in traumatized anterior teeth with pulp exposure. Pulpotomy medicament used was Biodentine. 2.5% Sodium hypochlorite used for haemostasis. Permanent restoration given was composite. Follow-up intervals were 3, 6 and 12 months. Electric Pulp Test (EPT) and cold test were used to evaluate the pulp status. Outcome evaluation was based on clinical and radiographic criteria.

**Conclusion:** On the basis of observations made from this study, it can be concluded that pulpotomy is a suitable alternative to RCT in traumatized anterior teeth with pulp exposure even if performed several days after

pulp exposure. Biodentine is a suitable bioceramic material for pulpotomy which promotes dentin bridge formation and protects the vitality of remaining portions of the pulp. Further research and clinical trials are also needed to develop treatment protocol to maximize clinical success.

**Clinical Significance:** Preservation of vitality of teeth has paramount importance as the vital pulp nourishes dentine and also forms reparative dentine in response to stimuli.

**Keywords:** TDI, EPT, RCT, VPT

### **Introduction**

Traumatic dental injuries (TDIs) occur frequently in children and young adults, comprising 5% of all injuries. Twenty-five percent of all school children experience dental trauma and about 33% of adults experience trauma to the permanent dentition:

In pre-school children (0.6 years) these injuries mainly result from falling during day time in the home environment. In school children (7-15 years) the injury mainly results from being pushed and hit, and from falling; these occur mainly in school or sports areas during day time.

Vital pulp tissue has the inherent capacity to produce reparative dentin in response to biological and pathological stimuli.

Vital pulp therapy (VPT) aims to preserve and maintain pulp tissue. In the absence of microbial contamination pulp tissue has the innate capacity for repair indicates that preservation of the pulpally involved permanent tooth through VPT is a treatment alternative.

A biocompatible material that can not only initiate healing and repair but also shield the pulp from further insult is placed over it. Various materials have been tried as pulpotomy medicament giving successful to detrimental results. Now, bioceramic materials have

become recognized as the gold-standard material for pulpotomy.

This study evaluates the treatment outcome following pulpotomy using bioceramic material in traumatized mature permanent anterior teeth based on clinical evaluation at 3,6,12 months follow-up and radiographic evaluation at 12 months or any time during the follow-up period if symptomatic. Clinically visible coronal discoloration and diffuse calcification were also assessed.

### **Clinical Description**

In this, study 60 patients of the age group 12-50 years satisfying the inclusion criteria were enrolled.

### **Inclusion Criteria**

- Cases of pulpotomy using bioceramic materials in permanent anterior teeth with traumatic exposure that can be reviewed over a period of 12 months.
- Patients reported within a period of 1 week following traumatic exposure.
- Patients who are willing to give signed informed consent.

### **Exclusion Criteria**

- Patients with luxation injuries and root fracture
- Patients with extensive crown fracture requiring post and core.
- Patients with debilitating systemic disease.
- Teeth in which no bleeding from the pulp chamber on access opening or pulpal bleeding could not be stopped within 10 minutes.

### **Pulpotomy Treatment Protocol**

After the administration of local anesthesia (Lignocaine hydrochloride 2% with adrenaline 1:100,000) rubber dam application was done and the crown was disinfected with 5% sodium hypochlorite (Fig 1) The roof of the pulp chamber was removed by using a

coarse, high-speed diamond bur. After pulp exposure, the cavity was flushed with 2.5% sodium hypochlorite. Partial removal of pulp was done. Hemostasis was achieved by the application of a cotton pellet moistened with 2.5% sodium hypochlorite for up to a maximum of 10 minutes. Biodentine was mixed and placed over the exposed pulpal tissue. Then a layer of RMGIC was placed over the material and light cured for 20 seconds. Finally a composite restoration was given over the RMGIC. Maxillary and mandibular impressions were taken for wax build-up. Polyvinyl siloxane putty index was made (Fig 1) and composite buildup done (Fig 2).

### Assessment of Treatment Outcome

Evaluation of treatment outcome will be based on clinical and radiographic examination.

### Clinical Criteria

1. Absence of spontaneous pain or discomfort.
2. No tenderness to palpation and percussion.
3. Soft tissue around the teeth is normal with no swelling or sinus tract.

### Radiographic Criteria

No root resorption, or new periapical pathosis.

### Outcome Measures

Success: Asymptomatic without radiographic signs of periapical pathology, followed up over a period of 12 months will be considered successful.

Failure: Tooth that became symptomatic with or without radiographic signs of periapical pathology, root resorption or asymptomatic with radiographic signs of periapical pathology followed up over a period of 12 months will be considered as failure.

Other variables to be measured are:

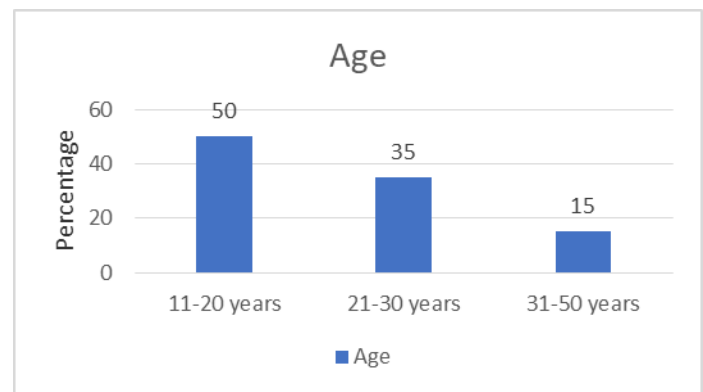
- Radiographically visible dentin bridge formation
- Diffuse calcification of root canal

During the follow up period the tooth was asymptomatic and gave positive response to pulp sensibility tests. At

12 month follow up, dentin bridge formation and diffuse calcification was noted and no signs of periapical pathology in the radiograph.

### Results

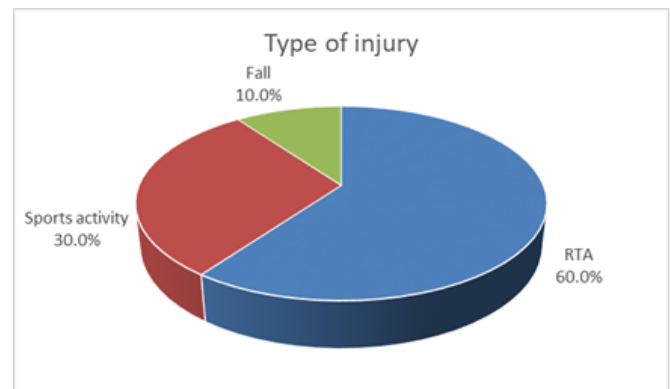
**Background characteristics:** Patients were in the age group of 11 – 50 years and their percentage distribution is given in Graph 1. About 50% of the patients were in the age group of 11-20 years. 35% were of age group of 21-30 years and only 15% were from 30-50 year group.



Graph 1: Percentage distribution of the sample according to age

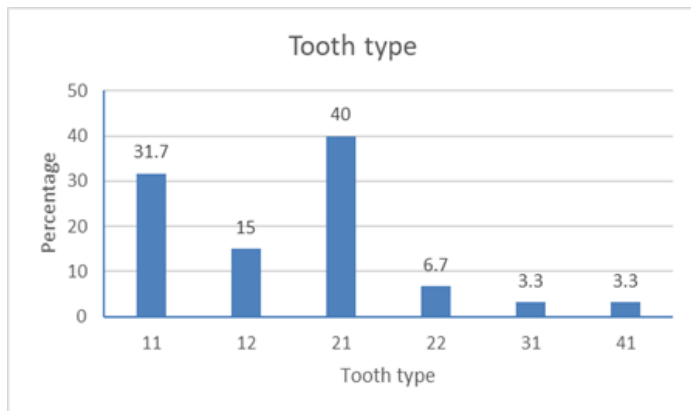
In this study 16.7% of patients were females and 83.3% were males.

It was noted that RTA (60%) was the most common etiology for patients who reported for treatment of traumatized anterior teeth. In 30% the etiology of trauma was sports activity and the remaining 10% had history of fall.



Graph 2: Types of injury

While considering the distribution of sample according to tooth type, tooth no: 21(40%) was the most commonly injured tooth followed by 11(31.7%), 12(15%), 22(6.7%), 31(3.3%) & 41(3.3%) in order.



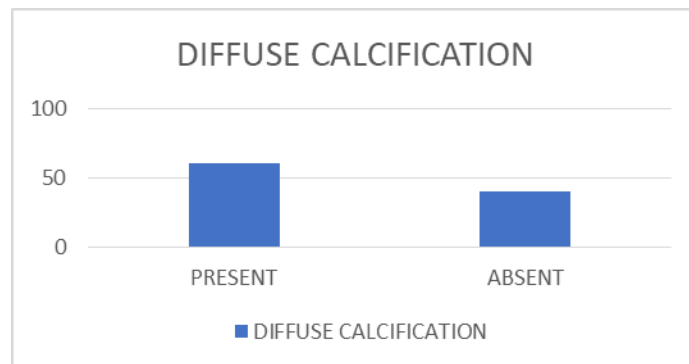
Graph 3: Percentage distribution of sample according to tooth type

In the radiographic examination of cases during follow-up period diffuse calcification of pulpal space was noted in 60% of cases and no calcification was detected in 40% cases.

Table 1: Elapsed before treatment

Time elapsed before treatment	Time to stop bleeding				Total		$\chi^2$	df	P
	≤ 5 Minutes		5-10 minutes						
	N	%	N	%	N	%			
<12 hours	4	6.67	0	0	4	6.67	60.0	3	<0.001
12-24 hours	11	18.34	0	0	11	18.33			
>48 hours	0	0	25	41.7	25	41.67			
Total	35	58.3	25	41.7	60	100			

While comparing the association between categorical variables using Chi-square test, it can be concluded that there was no association between age and time to stop bleeding, age and type of trauma, age and time elapsed before treatment, tooth and type of trauma with the outcome. A statistically significant association was noted in the time elapsed before treatment and time to stop bleeding (P= <0.001) with the outcome as in table 1. Dentin bridge formation and the quality of coronal



Graph 4: Percentage distribution of sample according to diffuse calcification

It was noted that as the time elapsed before treatment increases the time to stop bleeding also increased and it is also significant (p= <0.001).

restoration contribute the success of pulpotomy in all the cases. Dentin bridge formation was noted in 6 months and 12 months follow up periods which help to maintain the vitality of remaining pulpal tissue. Composite build-up was done in all cases using polyvinylsiloxane putty index. Coronal restoration was intact in almost all the cases which provided a bacteria tight seal for the success of pulpotomy.

## Discussion

Proper diagnosis, treatment planning, and follow up are important for achieving a favorable outcome. Trauma to the tooth is followed by pulpal hyperemia, alteration in the blood flow in the pulp, and over time can cause pulpal necrosis.

In this study, among the 60 samples studied males sustained injuries (83.3%) more than females (16.7%). S Petti et al in a meta-analysis found that the global prevalence ratio was 1.43, suggesting that males were 34%-52% more likely to develop TDI than females.

The incidence of complicated crown fractures ranges from 2% to 13% of all dental injuries.

In the present study it was found that tooth #21(40%) was the most commonly injured tooth followed by #11(31.7%), #12(15%), #22(6.7%), 31(3.3%) & 41(3.3%) in order.

R Nagarajappa et al found that maxillary central incisors were the most frequently affected teeth (83.7%), followed by maxillary lateral incisors (14.9%) and mandibular central incisors (1.4%).

A Ramachandran et al found that tooth #9 (38.5%) followed by #8 (33.9%) was commonly affected.

It was observed that pulpotomy offered a viable alternative to root canal treatment for teeth with vital pulps in the short term. However, there is insufficient clinical evidence to consider this technique for the treatment of every permanent tooth.

In a study both MTA and Biodentine showed similar clinical and radiographic outcomes when used as pulpotomy materials in the treatment of traumatized immature anterior permanent teeth.

In the present study Biodentine was used as a pulpotomy material, dentin bridge formation was noted in all cases and no coronal discoloration was observed in the follow-up period.

Biodentine (BD) is a suitable material for pulpotomies on anterior permanent teeth with complicated crown fracture. It does not cause significant discoloration and it allows root maturation.

The interval between trauma and treatment are not critical for pulp recovery provided that the pulp is vital, the superficially inflamed tissue is removed, and a proper aseptic procedure is performed using bio-compatible materials.

BD has been proven to be biocompatible (it does not damage pulpal cells in vitro or in vivo). It has a capability of stimulating tertiary dentin formation.

It was shown that when BD was applied directly onto the pulp, it induced an early form of reparative dentine synthesis, probably due to modulation of pulp cell TGF- $\beta$ 1 secretion.

In the present study, EPT and cold test were used to check the pulp status. During follow-up period the response threshold for pulpotomized tooth was higher when compared to contralateral tooth. Increasing the response threshold after pulpotomy may be a consequence of removing the rich nerve supply in the coronal pulp chamber.

## Conclusion

On the basis of observations made from this study, it can be concluded that pulpotomy is a suitable alternative to RCT in traumatized anterior teeth with pulp exposure even if performed several days after pulp exposure. Biodentine is a suitable bioceramic material for pulpotomy which promotes dentin bridge formation and protects the vitality of remaining portions of the pulp. Further research and clinical trials are also needed to develop treatment protocol to maximize clinical success.

## References

1. Levin, L, Day, PF, Hicks, L, et al. International Association of Dental Traumatology guidelines for the management of traumatic dental injuries: General introduction. *Dent Traumatol.* 2020; 36: 309– 313.
2. Crona-Larsson, G. and Norén, J.G. (1989), Luxation injuries to permanent teeth — a retrospective study of etiological factors. *Dental Traumatology*, 5: 176-179.
3. Levin L, Day PF, Hicks L, O'Connell A, Fouad AF, Bourguignon C, Abbott PV. International Association of Dental Traumatology guidelines for the management of traumatic dental injuries: General introduction. *Dent Traumatol.* 2020 Aug;36(4):309-313.
4. Ward, J. (2002), Vital Pulp Therapy In Cariously Exposed Permanent Teeth And Its Limitations. *Australian Endodontic Journal*, 28: 29-37.
5. Cvek M. A clinical report on partial pulpotomy and capping with calcium hydroxide in permanent incisors with complicated crown fracture. *J Endod.* 1978 Aug;4(8):232-7.
6. Seltzer s, Bender ib, Ziontz m. The dynamics of pulp inflammation: correlations between diagnostic data and actual histologic findings in the pulp. *Oral Surg Oral Med Oral Pathol.* 1963 Aug;16:969-77.
7. Bourguignon C, Cohenca N, Lauridsen E, Flores MT, O'Connell AC, Day PF, et al. International Association of Dental Traumatology guidelines for the management of traumatic dental injuries: 1. Fractures and luxations. *Dent Traumatol.* 2020 Aug;36(4):314–30.
8. Padawe D, Takate V, Dighe K, Kakade A, Makane S, Pathak R. Prevalence of Traumatic Injuries to Anterior Teeth in 9–14 Year School-going Children in Mumbai, India. *J Contemp Dent Pract.* 2019 May;20(5):622–30.
9. Pettis S, Glendor U, Andersson L. World traumatic dental injury prevalence and incidence, a meta-analysis-One billion living people have had traumatic dental injuries. *Dent Traumatol.* 2018 Apr; 34(2):71–86.
10. Aggarwal V, Logani A, Shah N. Complicated crown fractures – management and treatment options. *Int Endod J.* 2009 Aug;42(8):740–53.
11. Nagarajappa R, Ramesh G, Uthappa R, Kannan SPK, Shaikh S. Risk factors and patterns of traumatic dental injuries among Indian adolescents. *J Dent Sci.* 2020 Mar;15(1):96-103.
12. Ramachandran A, Khan SIR, Baskaradoss J. Epidemiology of traumatic dental injuries among adults in an indian sub-population [Internet]. In *Review*; 2019 Aug [cited 2021 Feb 11].
13. Simon S, Perard M, Zanini M, Smith AJ, Charpentier E, Djole SX, et al. Should pulp chamber pulpotomy be seen as a permanent treatment? Some preliminary thoughts. *Int Endod J.* 2013 Jan;46(1):79–87.
14. Abuelniel GM, Duggal MS, Kabel N. A comparison of MTA and Biodentine as medicaments for pulpotomy in traumatized anterior immature permanent teeth: A randomized clinical trial. *Dent Traumatol.* 2020 Aug;36(4):400–10.
15. Borkar S, Ataide I. Biodentine pulpotomy several days after pulp exposure: Four case reports. *J Conserv Dent.* 2015;18(1):73.
16. Haikal L, Ferraz dos Santos B, Vu D-D, Braniste M, Dabbagh B. Biodentine Pulpotomies on Permanent Traumatized Teeth with Complicated Crown Fractures. *J Endod.* 2020 Sep;46(9):1204–9.

17. Bhat S, Hegde S, Adhikari F, Bhat V. Direct pulp capping in an immature incisor using a new bioactive material. *Contemp Clin Dent.* 2014;5(3):393.
18. Laurent P, Camps J, About I. Biodentine™ induces TGF-β1 release from human pulp cells and early dental pulp mineralization: Biodentine induces mineralisation and TGF-β1 release. *Int Endod J.* 2012 May; 45(5):439–48.

**Legend Figures**

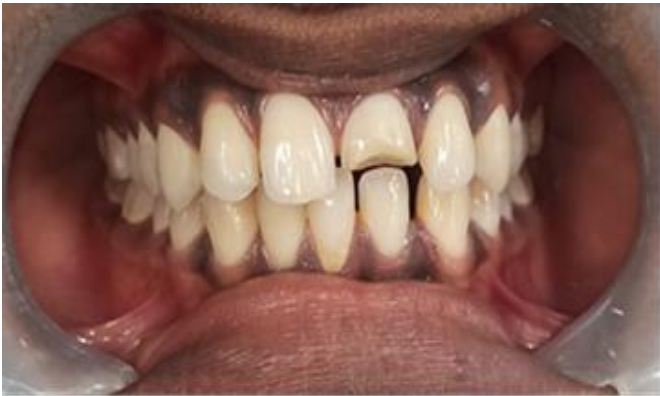

Figure 1: Pre-Operative Clinical View

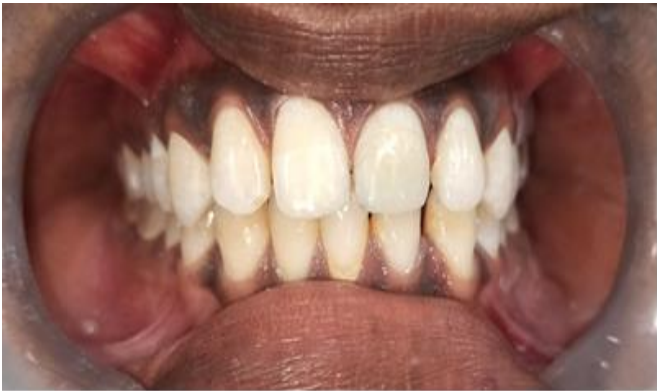

Figure 2: Post-Operative Clinical View